

# Arthroscopic resection of symptomatic medial synovial fold of the posterior cruciate ligament in bilateral knees

Jaewook Lee<sup>1</sup>, Jin Hwan Ahn<sup>2</sup>, Ingyu Lee<sup>2</sup>, Yongun Cho<sup>3</sup>

<sup>1</sup>Department of Orthopaedic Surgery, Bupyeong Himchan Hospital, Incheon, <sup>2</sup>Department of Orthopaedic Surgery, Kangbuk Samsung Hospital, Sungkyunkwan University School of Medicine, Seoul, <sup>3</sup>Department of Orthopaedic Surgery, Konkuk University School of Medicine, Chungju, Korea

We report a case of pathologic bilateral impingement of the posterior cruciate ligament (PCL) synovial folds referred to PCL plicae. A 40-year-old female was admitted to the hospital with vague bilateral knee pain along the medial side of both knees just below each patella. She reported that standing for long periods of time increased the pain and that it has been more than 10 years since the vague pain occurred. On magnetic resonance imaging, medial synovial folds of the PCL were identified and therefore knee arthroscopy was performed under general anesthesia. The arthroscopic findings revealed entrapped folds within the medial tibiofemoral joints when the knees were in passive extension. The entrapped tissue of the synovial folds was resected by punch forceps and debrided by a shaver. After eight months of surgery, the patient's symptoms completely resolved, and she regained full range of motion. The long medial synovial folds around the PCL can be a cause of knee pain due to entrapment between the femoral and tibial condyles. Plicae pathologies can therefore be considered one of the differential diagnosis of vague knee pain.

**Keywords:** Posterior cruciate ligament; Synovial fold; Arthroscopy

## INTRODUCTION

Synovial folds of joints have many physiologic functions, such as maintaining the stability of articulation, distributing pressure, and lubricating articular cartilage by secreting and reabsorbing synovial fluid [1,2]. However, under some conditions, the synovial fold may be a pathogenic factor. The synovial fold can cause pain in atlantoaxial and distal tibiofibular joints [1,2]. One article identified the relationship between fold type and impingement, between impingement and other internal derangement on knee arthroscopy [3]. Furthermore, similar to the synovial folds, plicae have been identified in multiple joints which have been shown to cause clinical symptoms, particularly when the structures become thickened or inflamed [4].

This article describes a case of pathologic bilateral im-

pingement of PCL synovial folds, otherwise known as PCL plicae.

## CASE REPORT

A 40-year-old female presented to the hospital with pain in both knees. The female was 159.5 cm in height, weighed 59 kg and had a body mass index of 23.2 kg/m<sup>2</sup>. She had no history of trauma or family history of similar joint pain. She reported that standing for long periods of time increased the pain and that it has been more than 10 years since the vague pain occurred. She found no pain relief despite strength training and activity modification through conservative treatment including painkillers at another hospital for a year. The knee pain affected her active life but she could perform daily living activities.

Received November 3, 2019; Revised March 5, 2020; Accepted March 18, 2020

Correspondence to: Yongun Cho, <https://orcid.org/0000-0002-9213-6989>

Department of Orthopaedic Surgery, Konkuk University Chungju Hospital, Konkuk University School of Medicine, 82 Gugwon-daero, Chungju 27376, Korea. Tel: +82-43-840-8250, Fax: +82-43-840-8964, E-mail: xanthone@naver.com

Copyright © 2020 Korean Orthopedic Society for Sports Medicine. All rights reserved.

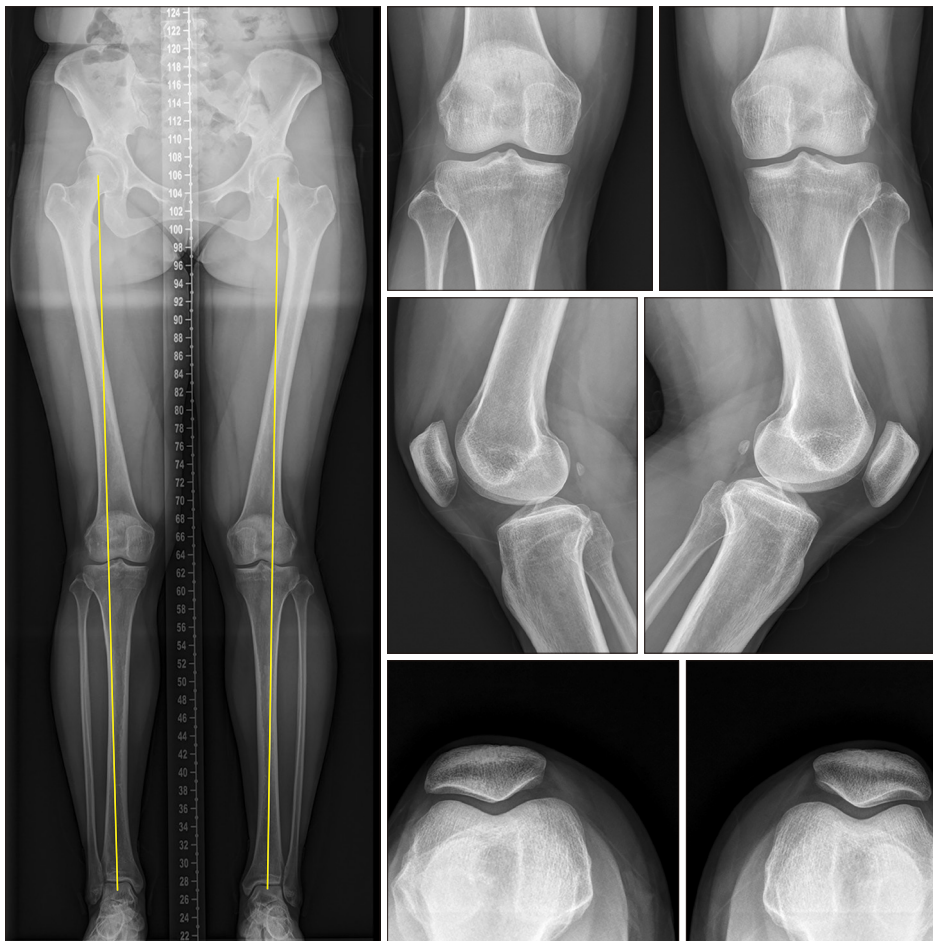© This is an open-access article distributed under the terms of the Creative Commons Attribution Non-Commercial License (<http://creativecommons.org/licenses/by-nc/4.0>) which permits unrestricted noncommercial use, distribution, and reproduction in any medium, provided the original work is properly cited.

However, walking and climbing the stairs aggravated the pain. The pain was relieved by resting and symptoms were similar for the left and right knees. There was no fever, loss of weight or appetite. She has no history of gout, rheumatoid arthritis or degenerative joint disease. Her objective clinical Lysholm score was 84 and International Knee Documentation Committee (IKDC) score was 74.2.

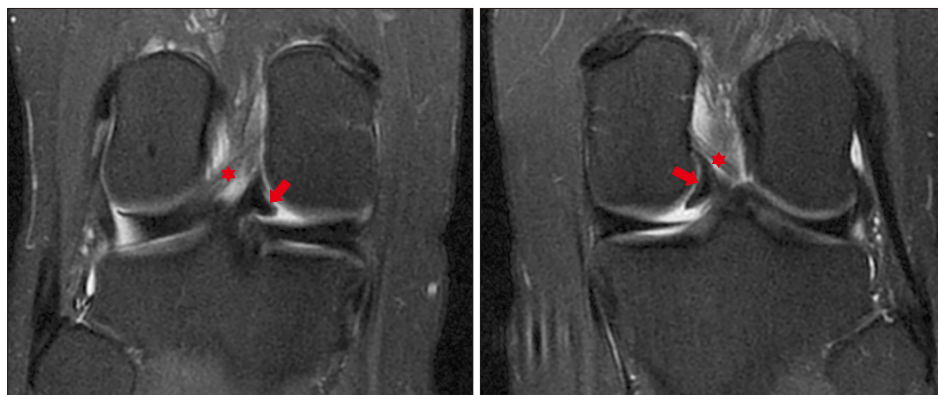
On a physical examination, there was no tenderness or swelling of the joint and the McMurray test was negative. There were no positive findings indicating patellofemoral joint symptoms or instability. Preoperative range of motion (ROM) was full without pain. Laboratory testing for urinary proteins and red blood cell casts was negative. Moreover, other laboratory analyses showed normal ranges: erythrocyte sedimentation rate (ESR), 11 mm/h, C-reactive protein (CRP), 0.38 mg/dL and RA factor was negative ( $< 10.0$  IU/mL). The other biochemical tests were within normal limits. In both knees, genu valgum was observed while standing on a lower extremity view and there were no specific findings on simple anterior-

posterior and lateral x-ray Merchant views (Fig. 1). On magnetic resonance imaging (MRI), there were medial synovial folds of PCL exceeding the imaginary line connecting the medial tibial condyle with the posterolateral aspect of the medial femoral condyle and there was no anterior or PCL tears or meniscus tears in either knee (Fig. 2).

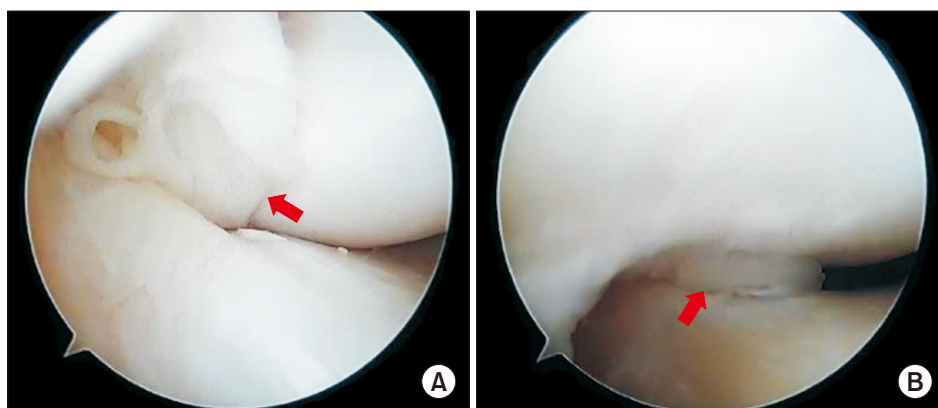
The knee arthroscopy was performed under general anesthesia. In the supine position, the knee was dropped down and the opposite knee was placed on the leg holder which was wrapped with an aseptic Mayo Stand Cover. There was no specific reason for starting the surgery from the right side. After making an anterolateral portal and confirming it through the scope, no abnormalities in the suprapatellar pouch were seen in the medial or lateral gutters. The medial and lateral menisci, medial femoral condyle and lateral femoral condyle were identified, and no specific findings were observed. The PCL synovial folds of approximately 10 mm were observed in both knee MRI findings. During passive knee extension, the



**Fig. 1.** X-ray images of both knees. The x-ray images including a standing lower extremity view, anterior posterior view, lateral view and Merchant view have no specific findings.



**Fig. 2.** The preoperative magnetic resonance imaging (MRI) of both knees. The coronal view of the preoperative MRI image. The meniscofemoral ligament (asterisks) arises from the posterior horn of the lateral meniscus and passes to attach to the lateral aspect of the medial femoral condyle. Note that bilateral posterior cruciate ligament plicae (arrows) are entrapped in the medial tibiofemoral joints.



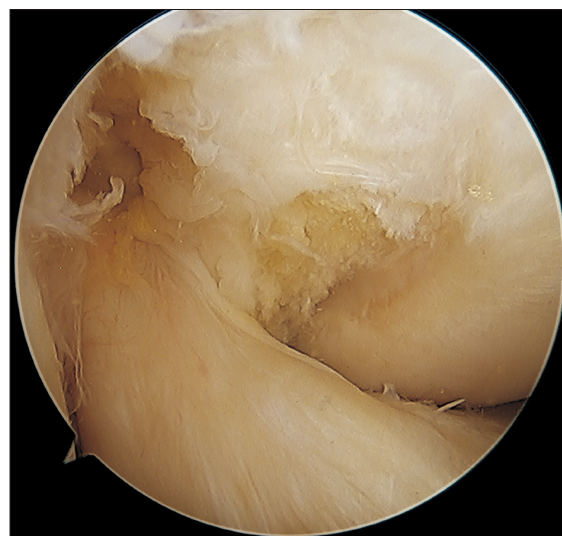
**Fig. 3.** The arthroscopic images during passive flexion (A) and extension of the right knee (B). The arthroscopic images show posterior cruciate ligament plicae (arrows) are entrapped especially during passive extension.

fold was entrapped in the medial tibiofemoral joint (Fig. 3). The entrapped tissue of the synovial fold was resected by punch forceps and debrided by a shaver via the anteromedial portal. The surgery was completed after confirming that remaining synovium was not entrapped (Fig. 4).

Partial weight bearing ambulation with crutches was started immediately and ROM exercises were encouraged. Two weeks following the operation, sutures were removed and there were no complications; full weight bearing mobility was initiated. After eight months of surgery, the patient's symptoms were completely resolved, and she had full ROM. Her objective IKDC score clinical scores improved from 74.2 to 83.5 and the Lysholm score improved from 84 to 97, 6 months after surgery. The patient was satisfied with the results of the surgery.

## DISCUSSION

The medial synovial fold of the PCL is a normal synovial structure that can be seen on MRI and in cadaveric studies [5]. One study reported 15 cases (88%) of PCL syno-



**Fig. 4.** The arthroscopic image of the right knee after the posterior cruciate ligament (PCL) plica is removed. Note that the PCL plicae are completely resected.

via folds among the 17 cadaver knees [5]. Kim et al. [6] reported that the prevalence of PCL synovial folds into the medial compartment of the knee joint was 47.0% in

their retrospective study using MRI. They suggested that this feature is unlikely to be related to the aging process because there was no significant relationship between prevalence and age, osteoarthritis, anterior cruciate ligament tears or medial meniscus tears [6].

In one histologic study, the synovial fold was found to be covered by several layers of synoviocytes, which suggests the tissue has a normal synovial structure in the knee joint [5]. However, in this case, impingement of normal tissue appeared to cause the pain. The synovial plicae in the knee are normal structures that represent remnants of synovial membranes from the embryological stage of development and sometimes cause symptoms [7].

Kim et al. [5] categorized synovial folds of the PCL into 3 types based on knee MRI. Type A had no definite medial synovial fold. Type B (inferior-short type) was a small synovial protrusion of the medial border. Type C (inferior-long type) had a fold that was long enough to extend beyond an imaginary line connecting the medial tibial spine to the posterolateral aspect of the medial femoral condyle. Knee MRI and arthroscopy showed Type C was associated with significant impingement, whereas types A and B did not [5]. Even minimal entrapment of the synovium can cause pain since the synovium is considered one the most pain sensitive structure is [8]. The

synovial folds in this case were found to be Type C as they were entrapped during passive knee extension in both knees.

During knee extension, the posteromedial (PM) bundle of PCL constricts, and the medial condyle of femur starts to move backwards against the concave up-slope of the medial tibial plateau, which provides greater congruity. The lateral femoral condyle also continues to roll forward and medially over the downslope, causing the femur shaft to rotate medially [9]. Thus, these authors suggest that this 'screw home movement' and constriction of PM bundle make impingement of the PCL during knee extension.

Although the PCL synovial folds are normal synovial structures, surgical excision is necessary if pain is caused by entrapment of the fold. Therefore, if there is vague pain that cannot be explained, careful observation of the PCL fold on MRI is needed. The authors obtained satisfactory results following arthroscopic removal of the PCL plicae of both knees.

## CONFLICT OF INTEREST

No potential conflict of interest relevant to this article was reported.

## REFERENCES

1. Tang XY, Liu LJ, Yang HJ, Peng MX, Liao SH. Anatomic study of the synovial folds of the occipito-atlanto-axial joints. *Clin Anat* 2007;20:376-81.
2. O'Sullivan E, Bowyer G, Webb AL. The synovial fold of the distal tibiofibular joint: a morphometric study. *Clin Anat* 2013;26:630-7.
3. Yoon KH, Tak DH, Park JS, Joo YB, Lee S. Medial synovial fold of the posterior cruciate ligament on knee magnetic resonance imaging and arthroscopy: retrospective investigation of impingement. *J Comput Assist Tomogr* 2016;40:799-802.
4. Casadei K, Kiel J. Plica syndrome. In: Abai B, editor. *StatPearls*. Treasure Island, FL: StatPearls Publishing; 2019.
5. Kim M, Lee S, Lee BG, Paik DJ, Bae J. The medial synovial fold of the posterior cruciate ligament: cadaveric investigation together with magnetic resonance imaging and histology. *J Comput Assist Tomogr* 2014;38:503-6.
6. Kim HS, Yoon YC, Park KJ, Wang JH, Choe BK. Interposition of the posterior cruciate ligament into the medial compartment of the knee joint on coronal magnetic resonance imaging. *Korean J Radiol* 2016;17:239-44.
7. Boles CA, Martin DF. Synovial plicae in the knee. *AJR Am J Roentgenol* 2001;177:221-7.
8. Kellgren JH, Samuel EP. The sensitivity and innervation of the articular capsule. *J Bone Joint Surg* 1950;32-B:84-92.
9. Rajendran K. Mechanism of locking at the knee joint. *J Anat* 1985;143:189-94.